

# Electrocardiogram (EKG) Interpretation

[WWW.RN.ORG](http://WWW.RN.ORG)®

Reviewed December 2022 – Expires December 2024  
Provider Information and Specifics available on our website  
Unauthorized Distribution Prohibited

©2022 RN.ORG®, S.A., RN.ORG®, LLC

Wanda Lockwood, RN, BA, MA

## Purpose:

The purpose of this course is to familiarize the nurse with different types of EKGs and the EKG waveform and to help the nurse to identify both normal and abnormal EKG findings.

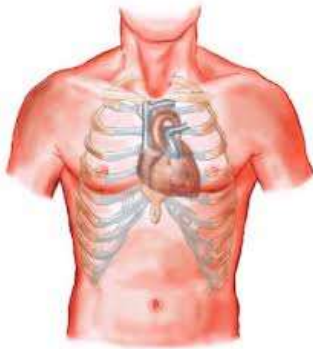
## Goals:

Upon completion of this course, the nurse should be able to:

- Describe heart anatomy.
- Describe the flow of blood through the heart.
- Outline the 5 phases of the cardiac cycle.
- Describe cardiac conduction.
- Describe the 5 phases of cardiac depolarization-repolarization.
- Draw and label the normal EKG waveform, P to U and explain each part of the wave.
- Discuss how different leads represent the heart.
- Explain placement of electrodes for 12-lead, 5-lead, and 3-lead EKGs.
- Outline 9 steps in interpreting the EKG.
- Describe EKG characteristics of atrial fibrillation, atrial flutter, wandering atrial pacemaker, and premature atrial complex.
- Describe EKG characteristics of sinus bradycardia and 4 types of heart block.
- Describe EKG characteristics of junctional rhythm, ventricular fibrillation, different types of ventricular tachycardia, and premature ventricular complex.
- Describe the difference between RBBB and LBBB.
- Describe asystole and pulseless electrical activity.

## Introduction:

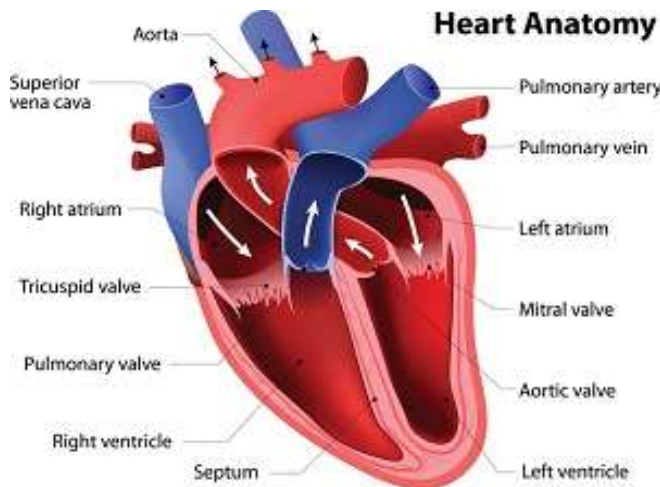
An electrocardiogram (EKG, ECG) is a record of the electrical activity of the heart. While the EKG cannot provide information about the mechanical functioning of the heart, it can demonstrate the rate and rhythm and abnormalities in conduction. Additionally, changes in the EKG may indicate enlargement of the heart chambers, cardiac ischemia or injury, cardiac infarct and electrolyte disorders as well as the effects of some drugs.



The heart is about 9 by 12 cm in size in the average adult and weighs 9 to 12 ounces (250-350 g). While newborns have only about 0.2 liters (one cup) of blood circulating, children over 5 or 6 and adults have about 4.5 to 5.5 liters of blood circulating.

With each heartbeat, the heart pumps about 60 to 90 mL resulting in circulation of 5 to 7 liters of blood every minute and 7600 liters per day with an average heart rate of 70 beats per minute. The normal heart ejects about 65% of the intraventricular volume in each cardiac cycle (referred to as the ejection fraction).

The heart lies in the mid chest with about one-third to the right of midline and two-thirds to the left. The top of the heart is at the second intercostal space and the apex at the fifth intercostal space in the adult. The infant's heart is more horizontal than the adult's, and the apex is at the left fourth intercostal space. By age 7, the child's heart is positioned as the adult's.



### Blood circulation:

Blood enters the heart through the superior vena cava into the right atrium. When the pressure in the right atrium exceeds that of the pressure in the right ventricle, the tricuspid valve opens, allowing the blood to flow into the ventricle until the pressure increases in the ventricle, forcing the tricuspid valve to close.

Meanwhile, the increased pressure in the right ventricle opens the pulmonary (pulmonic) valve (a semilunar valve) so the blood can enter the pulmonary artery and circulate in the lungs to exchange carbon dioxide for oxygen, returning to the heart through the pulmonary vein to the left atrium.

The increased pressure in the left atrium opens the mitral valve (AKA bicuspid valve) and the blood fills the left ventricle. As the pressure increases in the left ventricle, the mitral valve closes, the ventricles contract, and the aortic valve (also a semilunar valve) opens, and the blood enters the aorta and the general circulation. The time during which the left ventricle is filling with blood is referred to as diastole and pumping blood into the aorta as systole.

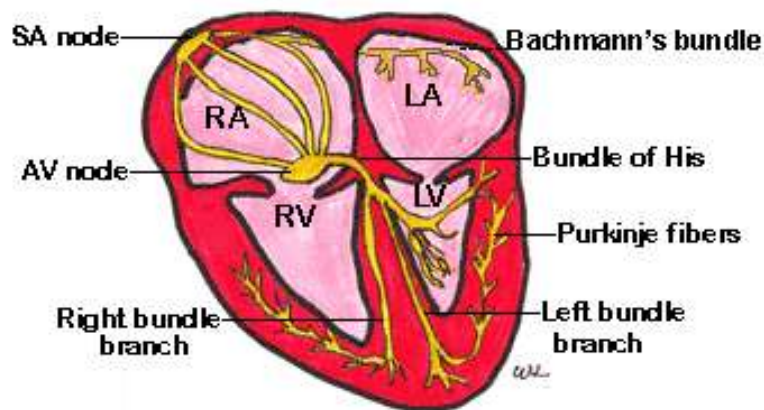
The atria contract simultaneously rather than sequentially and so do the ventricles: Both atria contract (lub) and then both ventricles (dub). When auscultating the heart, the heart sounds are those of the valves closing.

The coronary ostium is a small opening in the aorta that lies near the aortic valve. When the aortic valve is closed and the left ventricle is filling, blood flows through the coronary ostium and to the coronary arteries, so that the heart muscle is nourished first.

The **cardiac cycle** described above can be divided into 5 phases:

1. Isovolumetric ventricular contraction: With ventricular depolarization, pressure increases in the ventricles and the tricuspid and mitral valves close while the pulmonic and aortic valves remain closed as well.
2. Ventricular ejection: The pulmonic and aortic valves open, and the ventricles eject blood (ventricular systole).
3. Isovolumetric relaxation: The pulmonic and aortic valves close, the pressure in the ventricles falls, and the tricuspid and mitral valves remain closed. The atria fill (atrial diastole).
4. Ventricular filling: The tricuspid and mitral valves open and the ventricles fill with about 70% of ventricular volume (ventricular diastole).
5. Atrial systole (atrial kick): Provides the additional 30% of blood for the ventricles. The atrial kick (contraction of the atria) occurs with depolarization of atrial myocardial cells at the sinoatrial node (P wave) and is essential for adequate filling of the ventricles.

## **Cardiac conduction:**



In the normal heart, electrical impulses originate in the upper right atrium at the sinoatrial (SA) node (AKA the cardiac pacemaker). As the impulse leaves the SA node, it travels through Bachman's bundle to the left atrium and down the internodal tracts to the

atrioventricular (AV) node and from there down the Bundle of His to the bundle branches and ventricles, and to the Purkinje fibers.

Because the muscle of the left ventricle is thicker than that of the right, the impulses travel more rapidly down the left bundle branch than the right so that the ventricles can contract at the same time.

A fibrous ring that does not conduct electrical impulses separates the atria from the ventricles, so impulses must pass through the AV node to reach the ventricles (the reason an AV block may be life-threatening).

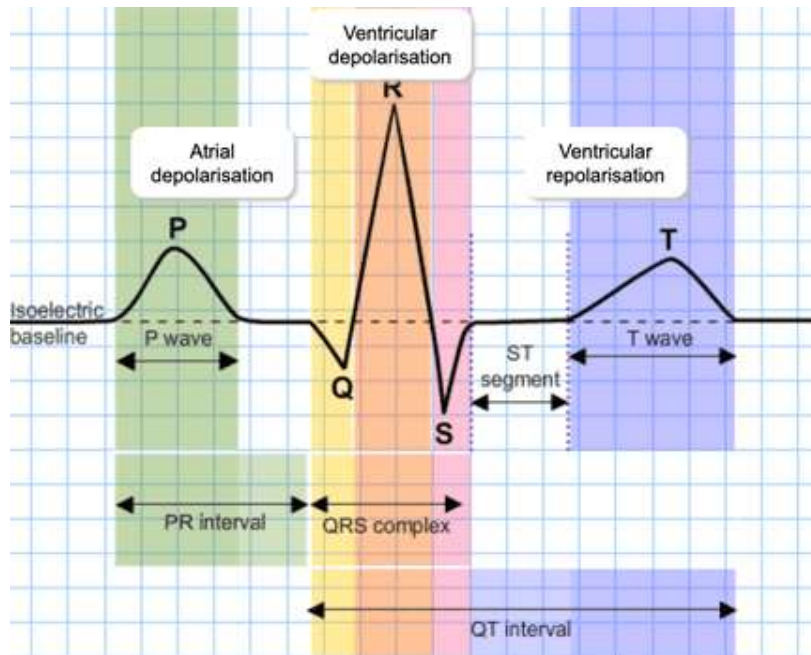
The SA node at rest fires 60 to 100 times in adults per minute and 60 to 190 times per minute in infants and children (depending on the age and level of activity) while the junctional tissue about the AV node (cardiac backup pacemaker) fires 40 to 60 times per minute in the adult and 50 to 80 times per minute in children younger than 3. The primary role of the AV node is to delay impulses by about 0.04 second so that the ventricles can fill adequately and don't contract too rapidly.

The Purkinje fibers not only conduct impulses but can also serve as a backup pacemaker, able to discharge between 20 to 40 times per minute in the adult and 40 to 50 times per minutes in children under age 3. Pacemaker cells in the junctional tissue (about the AV node) and the Purkinje fibers are usually not triggered unless conduction above is blocked. When impulses are transmitted backward toward the atria instead of downward from the atria, this is referred to as retrograde conduction.

The ability of cells, such as the SA and AV nodes to spontaneously initiate an impulse is referred to as *automaticity*. The degree of cell response (resulting

from ion shifts) is the *excitability*. The ability of cells to transmit electrical impulses is their *conductivity*, and the degree of contraction in response to the electrical impulse is the *contractility*.

The heart goes through **5 phases of depolarization-repolarization**:



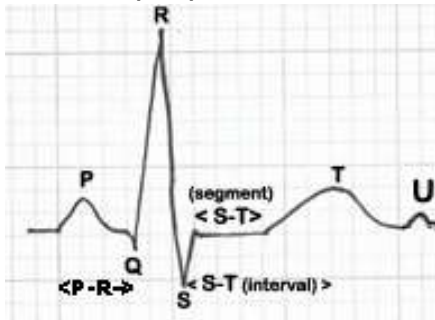
0: Period of rapid depolarization (contraction) during which sodium and calcium channels are open and sodium moves quickly into the cell and calcium more slowly.

1: Early repolarization during which the sodium channels close.

2: Plateau phase in which calcium continues to flow into the cell and potassium flows out. (Note that phases 1, 2, and the beginning of 3 are referred to as the refractory period because no stimulus can excite/depolarize the cell).

3: Rapid repolarization during which calcium channels close but potassium flows out of the cell at increased speed. (The last half of this phase is the relative refractory period because a strong stimulus may excite/depolarize the cell).

4: Resting phase during which the sodium-potassium pump allows potassium inside the cell and sodium outside while the cell becomes impermeable to sodium. Some potassium may flow out of the cell. The cell prepares for a stimulus. Note: When no electrical activity is taking place, the cells are considered polarized.

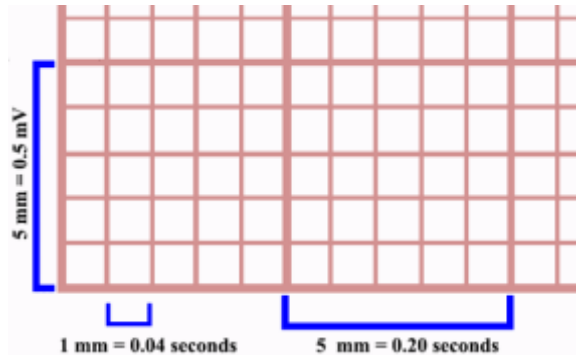


## Electrocardiogram and conduction

On the EKG tracing, the baseline is referred to the isoelectric line because there is no voltage during this time.

- **P-wave:** represents atrial depolarization (which causes contraction) as the electrical impulse spreads from the SA node through the atria (usually 0.08 to 0.10 second).
- **Isoelectric period:** A brief period follows the P wave and represents the time in which the impulse is traveling within the AV node (where conduction slows) and the bundle of His.
- **P-R interval:** Extends from the beginning of the P wave until the beginning of the QRS complex and reflects the time between the onset of atrial depolarization and the onset of ventricular depolarization. The duration usually ranges from 0.12 to 0.20 second.
- **P-R segment:** Extends from the end of the P wave until the beginning of the QRS complex and reflects an isoelectric period.
- **QRS complex:** Represents ventricular depolarization (contraction). The Q is downward deflection; R, upward, and S down (in most leads). The duration is usually 0.06 to 0.10 second. Prolongation of the QRS segment indicates impaired conduction. The shape of the QRS segment on the EKG tracing may vary from that above depending on the lead used or the presence of abnormal conduction. Atrial repolarization occurs during this time as well.
- **ST segment:** This isoelectric period represents a time period during which the ventricles are completely depolarized (plateau phase). The ST segment may be depressed or elevated with ischemia or hypoxia.

- **T wave:** Represents ventricular repolarization.
- **Q-T interval:** Represents the total time of ventricular depolarization and repolarization (from the beginning of the QRS segment to the end of the T wave). The duration is usually 0.2 to 0.40 second, but varies with heart rates. The higher the heart rate, the shorter the duration.
- **U wave:** This wave is sometimes present and represents remaining ventricular repolarization.

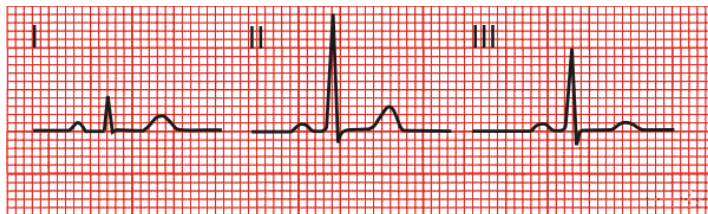


## Electrocardiogram basics

The electrocardiogram is recorded on special EKG paper or strips divided into large squares containing 25 small squares. On the horizontal axis, each small square is equal to 1 mm/0.04 second and each large square 5

mm/0.20 second on. So, a distance of five large squares is equal to 1 second. On the vertical axis, 5 mm (5 small squares) is equal to 0.5 mV. Thus, the vertical axis records amplitude/voltage; and the horizontal axis, time. Since one large square containing 5 small squares horizontally equals 0.20 second, 5 large squares equal one second.

The terms *electrode* and *lead* are sometimes used interchangeably, but the electrode is the disk with conductive gel that is placed on the patient's skin to record electrical impulses, which are converted by the electrocardiogram into a waveform. A lead, on the other hand, is the view of the electrical activity of the heart between a positive and negative pole. Therefore, the waveform may change direction or height in different leads. For example, a comparison of leads I, II, and III shows typical differences.



If electrical current travels toward a negative pole, the waveform deflects primarily downward and if toward a positive pole, the waveform deflects upward. If the current is perpendicular to the lead, the waveform may be

small in comparison to other leads or may go in both directions (biphasic).

That is, if the heart's electrical activity moves away from a positive electrode (toward negative), a negative deflection occurs. If the heart's electrical activity moves toward a positive electrode (away from negative), a positive deflection occurs.

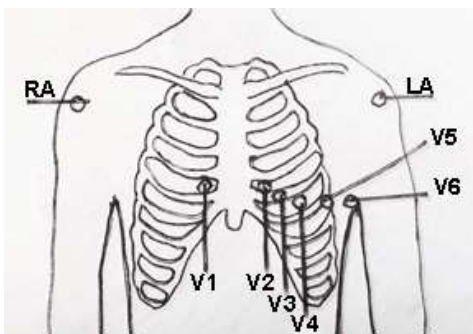
Location	AHA (American Heart Association)		IEC (International Electrotechnical Commission)	
	Inscription	Colour	Inscription	Colour
	RA	White	R	Red
	LA	Black	L	Yellow
	RL	Green	N	Black
	LL	Red	F	Green
	V1	Brown/Red	C1	White/Red
	V2	Brown/Yellow	C2	White/Yellow
	V3	Brown/Green	C3	White/Green
	V4	Brown/Blue	C4	White/Brown
	V5	Brown/Orange	C5	White/Black
	V6	Brown/Purple	C6	White/Purple

It's important to know that electrodes are labeled and color-coded and the labels and colors should always be verified before placement of electrodes. However, there are two organizations that have established labeling and color-coding standards: The American Heart Association and the International Electrotechnical Commission. These organizations use similar colors but in different configurations.

When performing an electrocardiogram or monitoring cardiac status, electrodes should be placed over dry, clean skin with adequate conductive gel.

The skin can be wiped with alcohol swabs, thoroughly dried, and then exfoliated with exfoliation paper. In some cases, hair may need to be clipped or shaved. Electrodes should not be placed directly over bone, scars, incisions, or irritated skin. The area of placement should be vigorously wiped with gauze to remove dead skin and to dry if skin is moist.

When placing electrodes about the heart, it's essential to always palpate and count the intercostal spaces to ensure proper placement. The first intercostal space is the space palpable immediately below the clavicle.



### 12-lead EKG

The 12-lead electrocardiogram utilizes 10 electrodes but obtains 12 different views of



the heart's electrical activity. Some leads have positive deflections (above isoelectric line) and others negative (below isoelectric line).

- **4 limb electrodes:** RA, LA, RL, LL. These electrodes should avoid heavily muscled areas. Limb leads should be placed symmetrically and can be placed on any part of the limb. However, if (for example), the arm electrodes are placed high on the upper arm, then the limb electrodes should be placed on the thighs; but, if the arm electrodes are placed lower, above the wrists, the leg electrodes should be also be placed lower, above the ankles. The right leg electrode provides a ground (neutral).

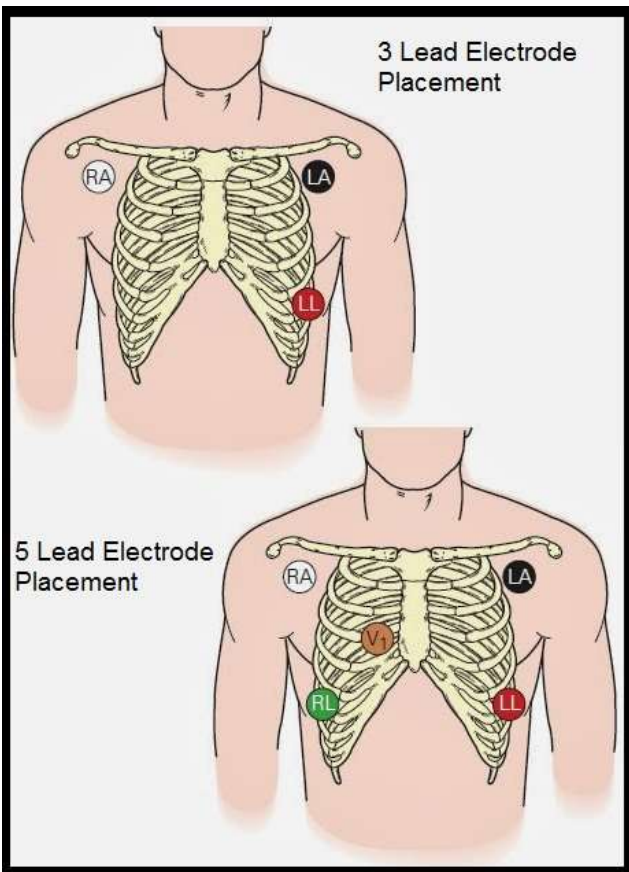
Note that protocols for placement of limb leads may vary somewhat. Some, for example, place all electrodes on the trunk. The RA and LA leads may be placed on the right and left upper chest near the shoulders and the limb leads on the right and left abdomen at about the level of waist, below the rib cage. This placement is especially used if the EKG is to be done with exercise.

- **6 precordial (in front of the heart/pericardium) electrodes:**
  - V1—Right sternum, 4<sup>th</sup> intercostal space
  - V2—Left sternum, 4<sup>th</sup> intercostal space.
  - V3—Half way between V2 and V4.
  - V4—Midclavicular line, 5<sup>th</sup> intercostal space.
  - V5—In line with V4 at anterior axillary line.
  - V6—In line with V4 and V5 at midaxillary line.

Note that proper placement of the electrodes is essential for proper diagnosis. If, for example, V1 and V2 are too high, this can result in T wave inversion that appears to result from an anterior MI.

There are **3 unipolar augmented leads**. The aV designation stands for "augmented voltage" because the low voltage must be augmented by the EKG machine in order to be visible.

- aVR: Positive electrode on right arm, producing a negative deflection. This lead may be used to show occlusion of the left main coronary artery.
- aVL: Positive electrode on left arm, producing a positive deflection. Provides a superior or high lateral view of the heart wall.
- aVF: Positive electrode on the left foot, producing a positive deflection and an inferior view of the heart wall.



### 3- and 5- lead EKG

**Three and five electrode placements** are commonly used for cardiac monitoring. Generally, a baseline 12-lead EKG should be taken prior to beginning cardiac monitoring.

For both 3 and 5-lead cardiac monitoring, usually all electrodes are placed on the trunk. RA and LA are usually placed on the lateral chest at the level of the 2<sup>nd</sup> intercostal space. For 5-lead monitoring, V1 is placed at the 4<sup>th</sup> intercostal space on the right of the mediastinum. The RL and LV limb electrodes are generally placed below the rib cage on the

right and left sides.

With three lead EKGs/monitoring, the limb electrode (LL) is the ground and can actually be placed anywhere away from the active leads. Placement of the active electrodes may vary somewhat depending on the lead to be recorded.

Because manufacturers may vary somewhat, it's important to always check manufacturer's instructions regarding the use of any monitoring system to ensure that electrode placement is correct and the equipment is correctly calibrated.

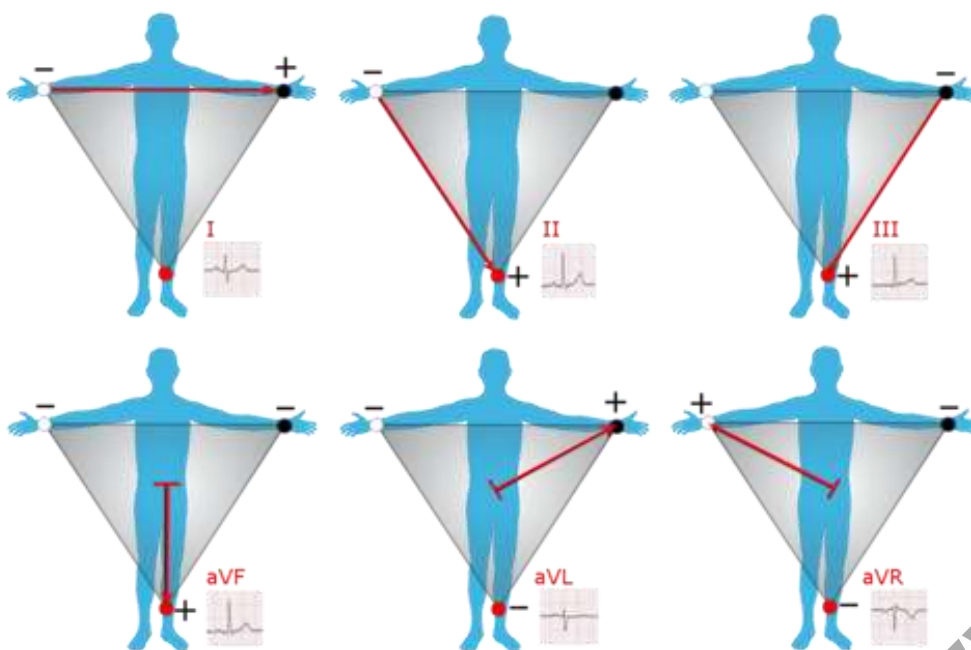
### Einthoven's triangle

The limb leads view the heart in the vertical plane; and the chest leads, the chest leads, the horizontal.

Lead I: Right arm—left arm. (Anterior view)

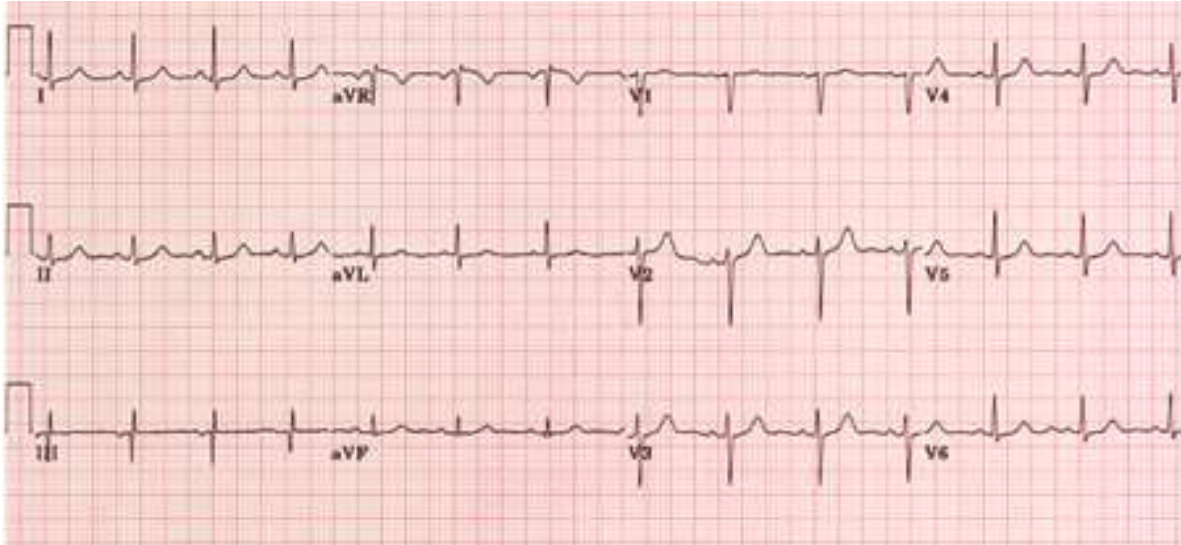
Lead II: Right arm—left leg. (Inferior view)  
 Lead III: Left leg—left arm. (inferior view)  
 aVR lead: Right arm.  
 aVL lead: Left arm. (Anterior view)  
 aVF lead: Left leg. (inferior view)  
 V1 to V3: Anterior view.  
 V3 to V4: Septal view.  
 V4 to V6: Lateral view.

Electrodes are placed in positions referred to as Einthoven's triangle. Note that leads I, II, and III form the three sides of an equilateral triangle.



Compare the different leads for a normal sinus rhythm in the illustration below. Note again that the deflection (up or down) depends on whether the electrical activity is moving toward or away from a lead.

© M. W. N. R. N. C.

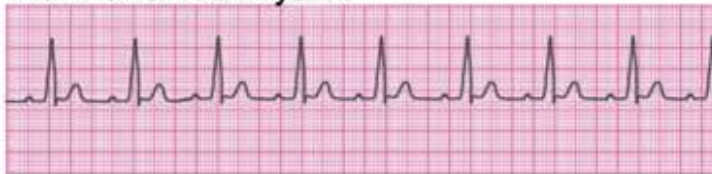

Lead II is the most commonly used for monitoring, so many EKG examples reflect those represented by lead II. If two leads are monitored, then leads II and V1 are most commonly used.

## Steps to interpreting the EKG

Before beginning to interpret EKGs, it's important to first recognize a normal sinus rhythm because this is the baseline to which all other rhythms are compared.

### Normal sinus rhythm



### Characteristics

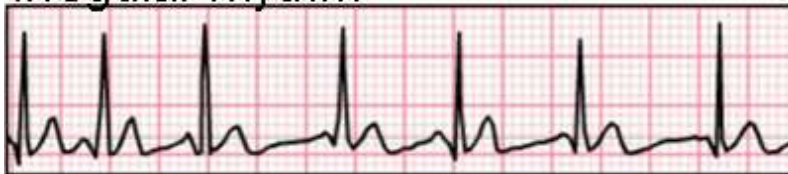- The rhythm is regular and the heartrate between 60 and 100.
- All P waves are of similar size and shape and upright (lead II) and a P wave is present before every QRS complex.
- QRS complexes are all similar in size and shape.
- The R-R interval (0.12-0.20 second) and Q-T interval (<0.12 second) are within normal parameters.
- T waves are upright and round (lead II).
- No abnormal beats are evident.

## Step 1: Assess rhythm

The rhythm is assessed to determine if it is regular or irregular. Assessing the rhythm is relatively easy and can often be determined simply by looking at the R waves on the EKG strip, but both the atrial rhythm (P to P) and the ventricular rhythm (R to R) should be assessed as they may vary with some arrhythmias. The rhythm can be assessed by counting large or small squares between waves or by using calipers or ruler to measure the distances.

In the normal sinus rhythm strip above, it's easy to see that there are 4 large squares between each P wave and each R wave, so the rhythm is regular. However, in the rhythm strip below, it's clear that the distance between both P and R waves vary from one beat to another, so the rates are irregular.

### Irregular rhythm

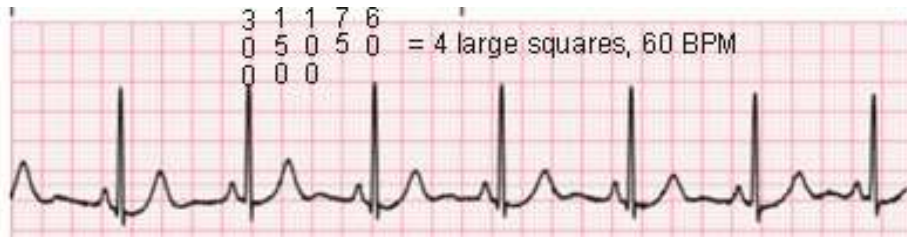


## Step 2: Calculate heartrate

Heartrate is easiest calculated by counting the peaks of the P waves (atrial rate) and R waves (ventricular) over a specified period of time. If it's clear that both the P waves and the R waves are present and the rhythm is regular, only the R waves need be counted because the R wave is easiest to identify.

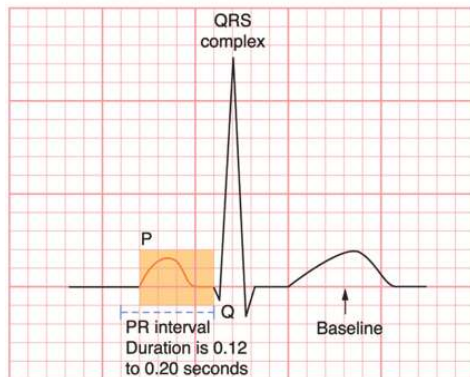
Many rhythm strips have small vertical 3-second markers (15 large squares separating them); therefore, these strips, such as the example below, are 6 seconds long, so calculating the heart rate is fairly straight forward for regular rhythms: count the rate for 3 seconds and multiply by 20 or for 6 seconds and multiply by 10. If the rhythm is irregular, then count for the longer period.

Every 5 small horizontal squares or one large square equals one second. Three beats per 3 seconds equal 60 beats per minute ( $3 \times 20 = 60$ ) and 4 beats per 3 seconds equal 80 beats per minute ( $4 \times 20 = 80$ ). Heart monitors automatically calculate the heartrate.



The heartrate is easy to estimate by using a sequencing method by memorizing the following chart and counting backward from 300 for every large square between the matching wave, such as from R to R. This method is easier to use if beginning the count on a wave that lines up even with a vertical line.

- 1 large square: 300 bpm.



- 2 large squares: 150 bpm.
- 3 large squares: 100 bpm.
- 4 large squares: 75 bpm.
- 5 large squares: 60 bpm.
- 6 large squares: 50 bpm.
- 7 large squares: 43 bpm
- 8 large squares: 37 bpm.

If, for example, there were 4 and a half boxes between waves, then the heartrate would be between 75 and 60.

Heartrates above 100 are classified as tachycardia and below 60 as bradycardia.

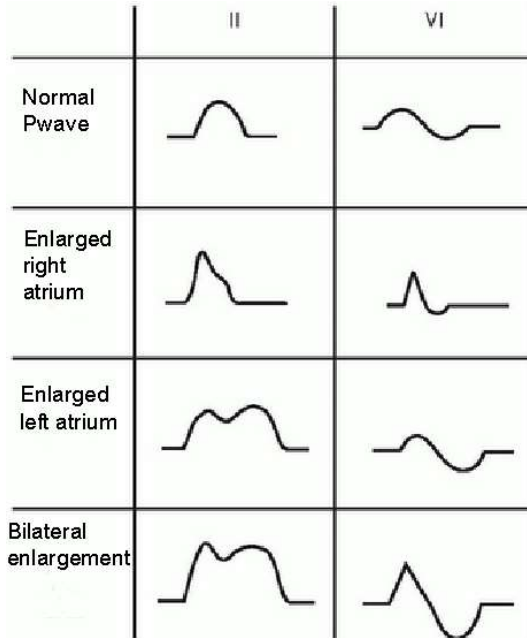
### Step 3: Assess P wave

The P wave reflects atrial contractions. The P wave should be smooth, rounded and upright and not notched or inverted and should be present before each QRS. The normal amplitude is between 0.5 and 2.5 mm in lead II and equal to or less than 0.12 second in duration.

(Remember that each small square vertically is equal to 1 mm and each small square horizontally is equal to 0.04 second, so the height may vary from half a small square to 2.5 small squares and the width should extend no more than 3 small squares.)

### Discussion:

The P wave represents activation (depolarization/contraction) of the right and left atria. The first third represents the right atrium; the middle a combination of both right and left activation, and the final third, the left. In

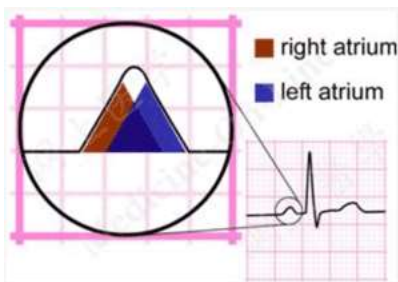


most leads, such as lead II, both waves go in the same direction, resulting in a monophasic P wave.

If, however the right atrium is enlarged, then right atrial activation may take longer than left atrial activation so that the waveform from the right extends to the end of the left activation, resulting in a P wave that is higher than normal because the two waveforms are combined. If, on the other hand, the left atrium is enlarged, the right atrial activation time is normal but the left atrial activation time is extended, resulting in a longer than normal P wave (which may be notched).

Remember that the appearance of the P wave varies depending on the lead. It is upright (positive) in leads I, II, V4-6, aVL, -aVR and aVF but variable in leads III and V1-3 and inverted (negative) in lead +aVR.

The wave may be biphasic in V1 and sometimes V2. This means that the waveform of right atrial activation and the left atrial activation move in opposite direction, so the initial (right) deflection is positive and the second (left) is negative.



If the P wave is missing, this can mean that there is a block masking the P wave. P waves that are not originating in the SA node may result in abnormally (saw tooth, flat, pointed, biphasic, notched, or inverted).

If P waves originate in the AV junctional tissue, they are inverted and may be located before the QRS complex, hidden in the QRS complex. or may even follow the QRS complex. With tachycardia, the P wave is often not visible.

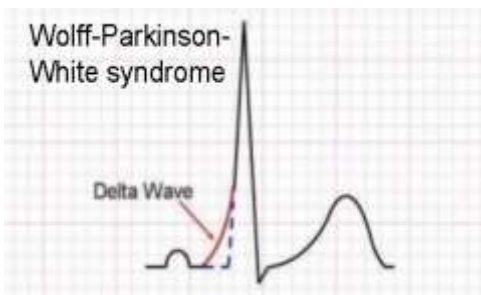
## Step 4: Assess P-R Interval

The P-R interval reflects the conduction system of the heart from the SA node through the atria, AV node, and His-Purkinje system. The P-R interval is more accurately a P-Q interval because it extends from the beginning of the P wave to the beginning of the QRS complex, that is from the beginning of contractions of the atria to beginning of contractions of the ventricles.

The normal duration of the P-R interval is 0.12 second (3 small squares) to 0.20 second (5 small squares). Assessment should determine if the P-R interval is normal, shortened, prolonged, or variable.

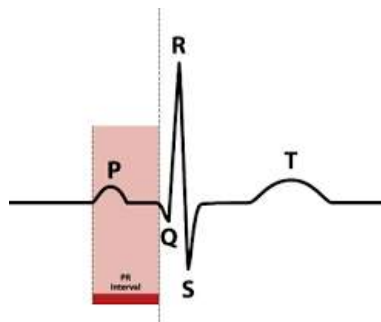
### Discussion:

The P-R interval may vary somewhat in normal physiologic states. For example, if the sympathetic nervous system activates and the pulse increases, the P-R interval shortens as conduction through the AV node speeds up. With deactivation, as the pulse slows, conduction also slows, so the P-R interval is prolonged. However, even with this variability, the P-R interval usually stays within normal parameters if there is no underlying cardiac abnormality.



If the P-R interval is shortened to less than 0.12 second, this generally indicates that the electrical conduction has bypassed the normal pathway (SA node through AV node) and the impulses have been conducted through accessory conducting tissue directly from the atria to the ventricles. This conducting tissue may lie between the atria and ventricles (Wolff Parkinson White Syndrome), between the atria and the AV node, or between the AV node and the ventricles.

With the Wolff-Parkinson-White syndrome, the short P-R interval presents a *delta* wave, which has a slurred upstroke into the QRS complex, which is prolonged.



Shortened P-R intervals are often associated with paroxysmal supraventricular tachycardia and palpitations and other EKG abnormalities.

If the P-R interval is prolonged to greater than 0.20 second, this can represent heart block. Some medications, such as beta blockers, can result in prolongation of the P-R interval. Additionally, some very well-conditioned athletes may develop a



normal prolonged P-R interval. Occasional prolonged P-R intervals are usually asymptomatic.

If the P-R interval before each QRS is uniformly prolonged, this generally indicates first degree heart block. If the P-R intervals are progressively prolonged until the P wave disappears, this represents second-degree AV block (Mobitz type I), which is usually reversible with treatment. Third degree AV block (Mobitz II), however, (characterized by missing QRS) is usually not reversible and requires a permanent pacemaker.

## **Step 5: Assess QRS complex**

The QRS complex, which represents ventricular contraction and is the largest part of the wave, is 0.06 to 0.12 second (3 squares) in duration. Amplitude, based on the height of the R wave, varies from  $\leq 5$  mm in frontal plane leads to  $\leq 10$  mm or less in precordial leads with lead V4 generally exhibiting the tallest R wave.

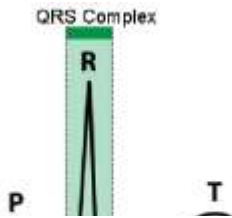
The Q wave (septal depolarization) is the first negative deflection after the P wave, with duration of  $\leq 0.04$  second and amplitude less than a third of the amplitude of the R wave on the same lead.; the R wave (ventricular depolarization), the first positive deflection after the Q wave; and the S wave (Purkinje depolarization), the first negative deflection after the R wave, extending further below the baseline than the Q wave.

During assessment, it's important to check first to see if the QRS complexes are present or absent and that they all follow P waves. Note whether there are more or fewer P waves than QRS complexes. Survey the amplitude and duration to determine if they are within normal parameters and note if the QRS complexes have an unusual appearance (tall, low, notched, prolonged, chaotic) or are inverted.

Note: if the R wave is missing, the complex is referred to as the QS complex. If the Q wave is missing, the complex is referred to as the RS complex.

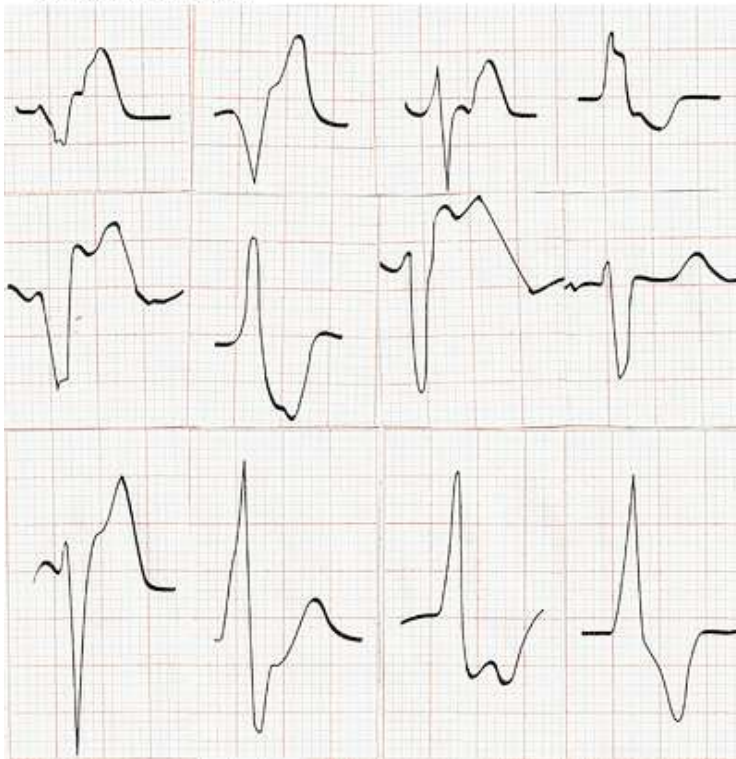
### **Discussion:**

Normal sinus rhythm and supraventricular dysrhythmias generally have normal QRS complexes. Abnormal QRS complexes, produced by abnormal ventricular depolarization, can result from a number of factors.



QRS amplitude varies according to the lead and amplitude tends to be higher in males than females. Most QRS complexes with high amplitude results from

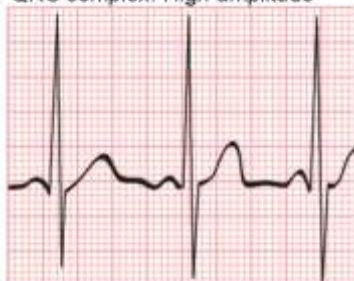### Wide QRS



ventricular hypertrophy, abnormal pacemaker, or beats conducted aberrantly. Left ventricular hypertrophy can result in increased amplitude  $>0.16$  second although occasional decreased amplitude may occur. Increased amplitude may also occur with right ventricular hypertrophy. Ventricular dysrhythmias may result in a wide variety of bizarre-looking prolonged QRS complexes with T waves that that may go in an opposite direction from the R waves. Wide QRS complexes may be associated with idioventricular rhythm, ventricular tachycardia, third degree AB heart block, RBBB,

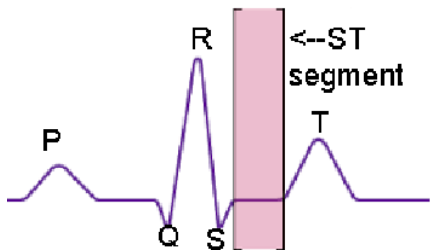
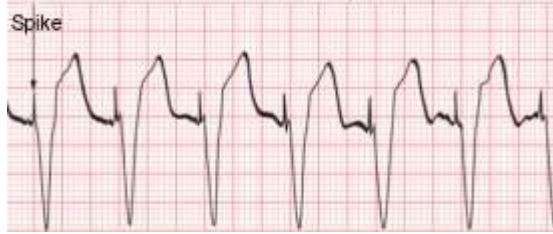and LBBB. Wide QRS complexes are a key finding with ventricular dysrhythmias.

QRS complex: High amplitude



© WWW.NRN.COM

### Pacemaker-induced QRS



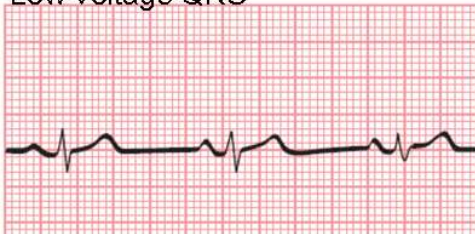
Low-voltage (amplitude) QRS complexes are those with voltage of less than 5 mm in all limb leads or 10 mm in all precordial leads and may occur in patients who are obese or have hyperthyroidism or pleural or pericardial effusion. Young women who are thin may have low voltage QRS complexes as a normal

variant. Air, fat, and fluids all have a dampening effect on the QRS complex. Pericardial effusion produces a triad of signs that include low voltage QRS, tachycardia, and electrical alternans (alternate beat variation).

Pacemaker-induced QRS complexes are often bizarre in appearance,  $\geq 0.12$  second in duration and preceded by a pacemaker spike. When a pacemaker is utilized, no SA impulses go through to the ventricles. If, however, a demand pacemaker is in place and only triggers when the heart rate falls, then the patient's EKG may not be distinguishable from those without a pacemaker except for paced beats.

### Step 6: Assess ST segment

#### Low-voltage QRS



The ST segment is an isoelectric period during which there is no electrical activity. The ST segment should be even with the baseline and curve into the T wave. The duration is 0.005 to 0.15 second (3.75 small squares).

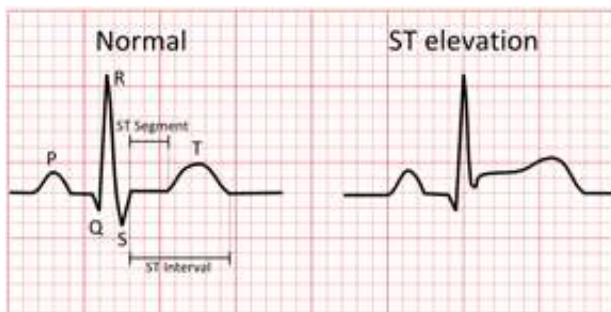
### Discussion:

The point where the ST segment starts is the J (junction) point and is used along with the base isoelectric line (PR) to measure the degree of displacement when determining whether there is deviation (elevation, depression) of the ST segment. The ST segment may alter with a number of different conditions, so it should be carefully assessed. Deviations can occur with acute cardiac myocardial ischemia.

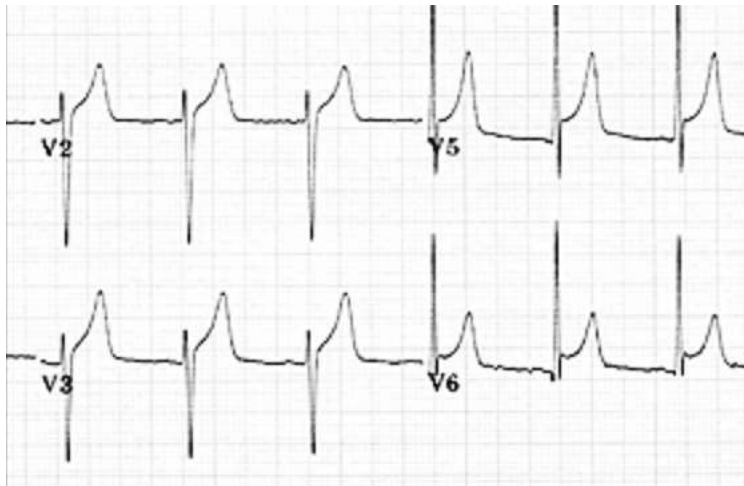
ST-elevation MI (STEMI) is a severe heart attack in which 100% occlusion occurs in one of the major coronary arteries. With acute transmural injury, such as may occur with an acute anterior MI, the ST segment usually has a convex upward or straightened appearance rather than concave

ST elevation may also be seen with Prinzmetal's angina, exercise-related transmural ischemia, and ventricular aneurysm after MI with pericarditis, a concave upwards elevation is found in most leads (except aVR). PR segment depression may also occur in conjunction with the ST elevation if there is atrial injury. Other causes of ST elevation include left ventricular hypertrophy and LBBB.

The S-T segment may be slightly elevated or high as a normal variant in the precordial leads V2-V6, so the patient's symptoms and laboratory findings must be assessed as well.

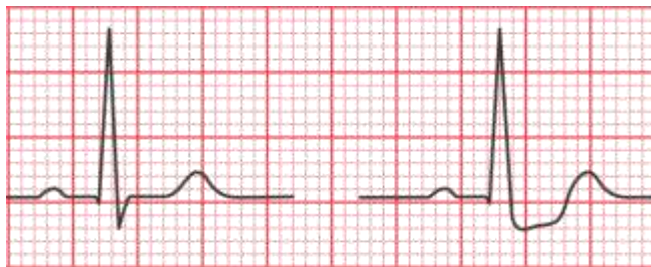


© WWW.RN.C



It's important to realize that non-cardiac conditions, such as increased ICP, stroke, peritonitis, spinal cord injury and pulmonary embolism as well as some drugs (digitalis, isoprenaline, quinidine, hyperkalemia, hypothermia, and pulmonary embolism) can all cause elevation of the ST segment.

ST segment depression may be horizontal, upward sloping or downward sloping and often indicates myocardial ischemia. ST depression may occur with non-ST-elevation MI (NSTEMI), which involves a severely narrowed but not completely blocked coronary artery.



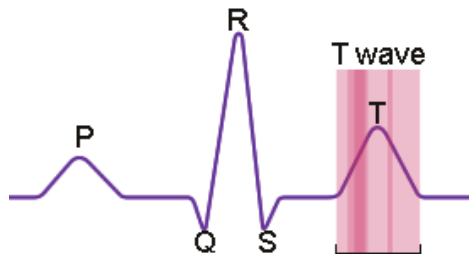
There are also a number of other (including non-ischemic) causes for ST depression. The mnemonic DEPRESSED ST helps to outline causes:

	Normal	ST Depression
D		Drooping valve (mitral valve prolapse)
E		Enlarged left ventricle.
P		Potassium loss (hypokalemia)
R		Reciprocal ST depression (inferior MI)
E		Encephalon hemorrhage
S		Subendocardial infarct
S		Subendocardial ischemia
E		Embolism (pulmonary)
D		Dilated cardiomyopathy
S		Shock
T		Toxicity (digitalis, quinidine)

## Step 7: Assess T wave

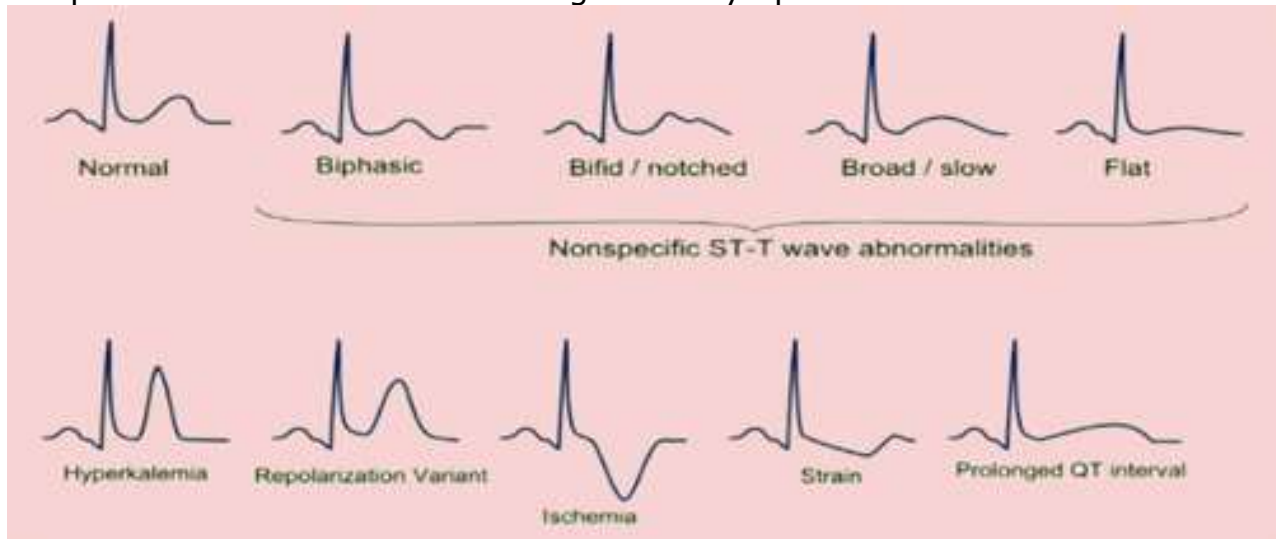
The T wave deflects upward in all leads except aVR, aVL, III, and V1 and has an amplitude of  $\leq 5$  mm in limb leads and  $\leq 10$  mm in precordial leads. The duration is 0.10 to 0.25 second. The shape is usually rounded at the peak and asymmetrical.

Abnormalities of the T wave represents problems with ventricular repolarization and are often associated with ST segment elevation or depression.



### Discussion:

A number of variations may be found in the shape and size of the T wave and the findings on the EKG should be assessed in relation to the patient's condition and other signs and symptoms:

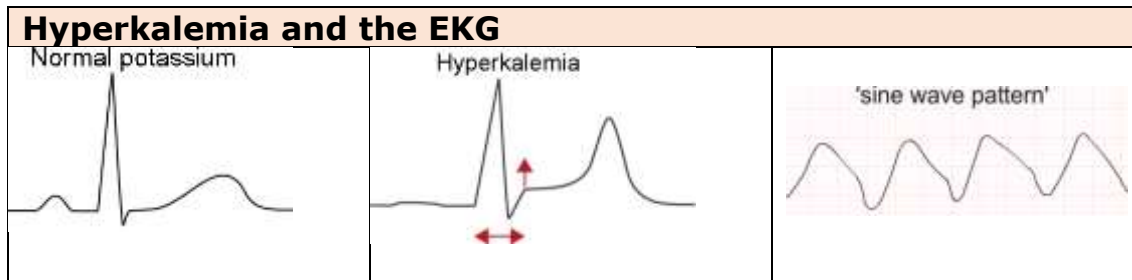


Elevated T waves are often non-specific and may be a normal variant in young patients and athletes. Some patients presenting with severe substernal chest pain related to acute onset of transmural myocardial ischemia (STEMI) may have very tall T waves that appear within 30 minutes of 100% coronary artery occlusion.

Elevated T waves (tall, peaked) can be an indication of hyperkalemia, which is also associated with absence of the P wave, with widening of the QRS complex.

and elevation of the ST segment. The changes associated with hyperkalemia are best seen in the precordial leads.

As the hyperkalemia worsens, the changes become more pronounced and eventually a sine wave pattern occurs and finally ventricular fibrillation and death. Potassium is critical for maintenance of the normal electrical activity of the heart.



The T wave is infrequently inverted in the adult although inversions may occur in V1-V3; however, the inverted T wave may be a normal variation in children and adolescents. T wave inversion is often associated with myocardial ischemia (unstable angina, NSTEMI, sepsis, severe anemia) but is less specific than ST depression.

Conditions that may result in transient T wave inversion include cardiogenic non-ischemic pulmonary edema, gastroenteritis, subarachnoid hemorrhage, **INVERTED T-WAVE** Takotsubo cardiomyopathy, and pheochromocytoma.



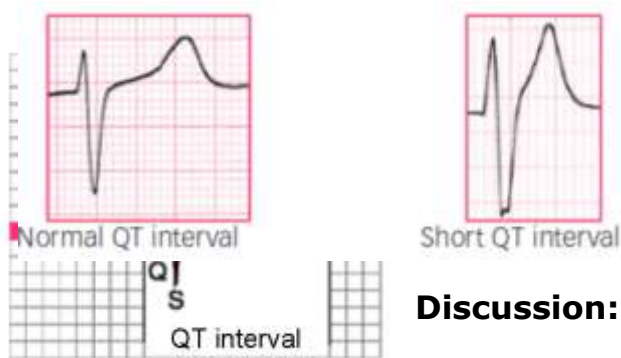
Wellens syndrome (marked stenosis of proximal left anterior descending coronary artery) is associated with deep, symmetrical inverted T waves in the anterior precordial leads.

Causes of permanent inversion may include pericarditis, cardiac metastasis, myocarditis, hypertrophic cardiomyopathy, athletic heart disease, and post tachycardia and right ventricular pacing. When associated with severe injury to the central nervous system (stroke, subdural hematoma, TBI), symmetric T wave inversions are often found along with prolongation of the QT interval.

## Step 8: Assess Q-T interval

The Q-T interval is that between the beginning of the QRS complex and the end of the T wave, representing both ventricular depolarization and repolarization.

Normal duration is generally considered between 0.36 to 0.44 second (360 to 440 ms), but there is not complete agreement among authorities. The QT interval is usually measured in lead II or alternately leads I or V5.

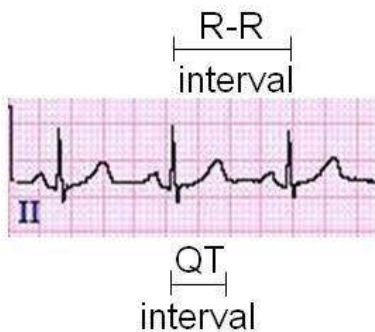


An abnormal QT interval is greater than 0.45 second (450 ms) in a male and greater than 0.47 second (470 ms) in a female as females tend to have longer QT interval than males.

### Discussion:

When determining whether the QT interval is prolonged, measure the distance between the RR interval and check where the T wave ends. If the T wave ends past the halfway duration of the R-R interval, then the Q-T interval is prolonged.

A prolonged QT interval may result from hypocalcemia, hypomagnesemia, and hypokalemia as well as some medications (haloperidol, methadone, vemurafenib, ziprasidone, astemizole, macrolides, and fluoroquinolones) and disease states (intracranial hemorrhage, hypothyroidism, rheumatoid arthritis and long QT syndrome). Prolonged QT interval increases the risk of developing ventricular arrhythmias, such as ventricular fibrillation.



Because heart rate affects the QT interval duration, the corrected QT interval (QTc) is frequently utilized based on Bezett's formula:

- $QTc = QT \text{ interval} \div \sqrt{\text{R-R interval}}$

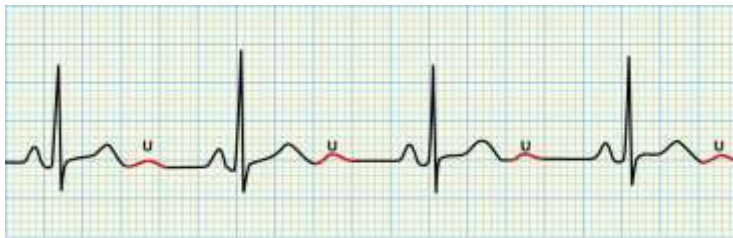Other formulas are also used to try to account for variations related to heartrate. To estimate the QTc, assume that a normal QTc for a heartrate of 60 is  $\leq 0.42$  second (420 ms) and subtract 0.02 second (20 ms) for every increase of 10 bpm. Thus, the QTc for 70 beats per minute would be  $\leq 0.40$  (400 ms).



Shortened QT intervals, which represents accelerated cardiac repolarization, are much less common and may be associated with a rare inherited condition (short QT syndrome) but may also be acquired, usually because of electrolyte disturbances (hypercalcemia, hyperkalemia, acidosis) or medications (digitalis, androgens)

## Step 9: Assess presence of U wave

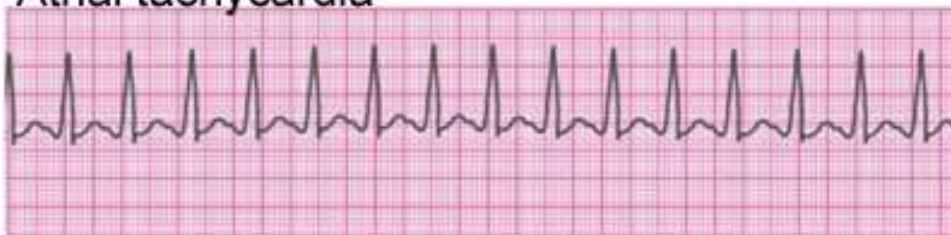The U wave is sometimes present on the EKG, usually seen in leads V2, V3 and V4 and in those with prominent T waves. The deflection is positive and the amplitude is usually about one quarter that of the T wave.



**Recognizing cardiac**

**abnormalities**

Atrial tachycardia



This is a form of supraventricular tachycardia that has a rate of 150 to 250 bpm. This rapid rate shortens diastole (atrial kick is lost), so cardiac output is decreased, resulting in decreased blood flow to the coronary arteries and myocardial ischemia.

If the atrial tachycardia has a regular rate and rhythm the P wave should be present with every QRS but it may not be visible because of the speed of contractions. In this type of tachycardia, the QRS complex usually appears normal. The T wave is also usually normal but may be inverted if the heart becomes ischemic, especially if the tachycardia is prolonged.

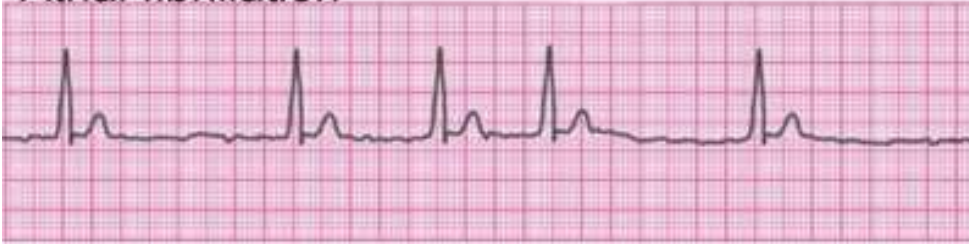### **Variations:**

**AT with block:** The conduction through the AV node becomes impaired with the rapid heartrate as the AV node begins to block impulses to protect the ventricles. Typically, the heartrate is between 150 and 250. When the block is present, more than one P wave occurs before each QRS; otherwise, the P wave may be hidden. The block may be constant (resulting in a regular rhythm) or variable (irregular rhythm). QRS is usually normal but may be prolonged with block.

**Multifocal (chaotic) AT:** Firing occurs at multiple ectopic atrial sites at rates usually ranging from 100 to 130 bpm (although it may occur at lower rates). The rhythm is typically irregular with variability in appearance of P waves (each site of atrial origin producing a different-appearing P wave). QRS is usually normal, but the P-R interval may vary depending on how close the atrial trigger is to the AV node. MAT is most often associated with chronic pulmonary disease and hypoxia but may also occur with CHF, acute MI, mitral stenosis, and electrolyte imbalances (hypocalcemia, and hypomagnesemia).

**Paroxysmal AT:** PAT occurs intermittently and occurs between episodes of normal sinus rhythm, usually at a rate of 150 to 250 while occurring. The rate is regular but the P wave is abnormal and may be hidden but should be present for each QRS. The P-R interval is the same for all cycles. The QRS may be normal or abnormal. PAT is often preceded by PACs that trigger the PAT.

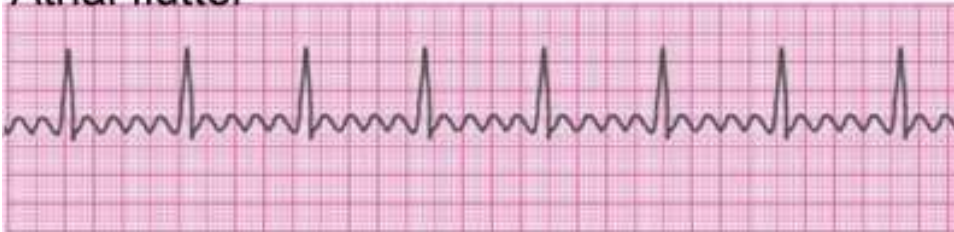## Atrial fibrillation



Afib is the most common atrial arrhythmia and is associated with atherosclerosis, rheumatic heart disease, CHF, thyrotoxicosis, MI, cardiomyopathy, valvular disease, congenital heart disease, pulmonary disease, and post-surgical cardiac procedures. This rapid pattern of disorganized atrial contractions has a rate of 400 to 700 but the ventricular rate may vary from 110 to 160 because of block of the extra beats at the AV node.

The rhythm is irregular, P waves absent (so P-R interval cannot be assessed), and QRS usually normal but may appear abnormal if rate very rapid. Because the rapid atrial rate makes the atria quiver, atrial kick is lost, resulting in decreased cardiac output.

## Atrial flutter



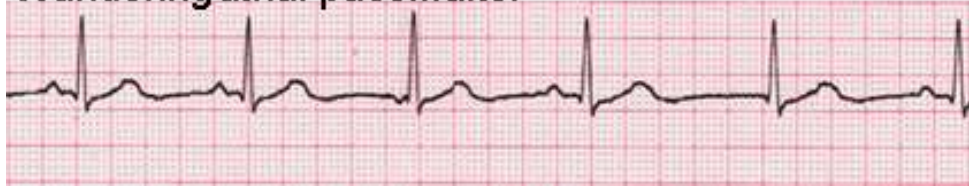This is a form of supraventricular tachycardia. The atrial depolarization/contraction rate ranges from 250 to 460 but the most common atrial rate is 300, and the most common ventricular rate is 150 (2:1) although it may on occasion be as high as 300 (1:1), depending on the amount of block that occurs at the AV node.

The atrial rhythm is usually regular with a fixed counterclockwise (occasionally clockwise) impulse in a reentry circuit. The ventricular rate may be irregular or regular, depending on the amount of block.

P waves appear as flutter (F) waves in a sawtooth pattern. The F waves may be hidden with rapid heartrates. The P-R interval may be consistent or varied, and the QRS complex is usually normal although abnormalities may occur. Atrial flutter is considered a form of supraventricular tachycardia.

Atrial flutter is associated with rheumatic heart disease, atherosclerotic heart disease, CHF, MI, myocardial ischemia, thyrotoxicosis, and post-cardiac surgery

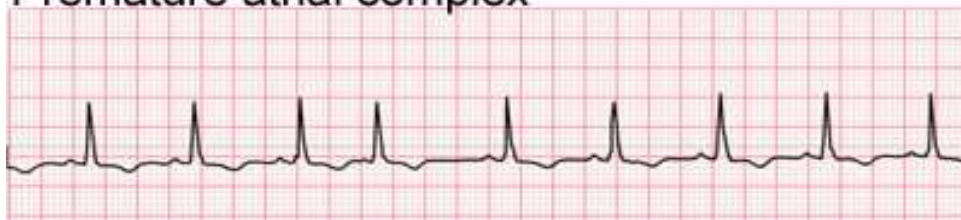### Wandering atrial pacemaker



A wandering atrial pacemaker is characterized by stimuli arising from different supraventricular sites, some from the SA node, some from other sites in the right atrium, and some from the AV junctional tissue.

This arrhythmia is often transient and may occur as a normal variant in young patients and athletes. Note the different shapes of the P wave (depending on the stimulus). The rhythm is irregular but the heart rate is usually normal or bradycardic. The P-R interval may vary but the QRS complex and T wave usually appear normal although the Q-T interval may vary. This arrhythmia is usually not serious but may be caused by rheumatic carditis and digitalis toxicity.

### Premature atrial complex

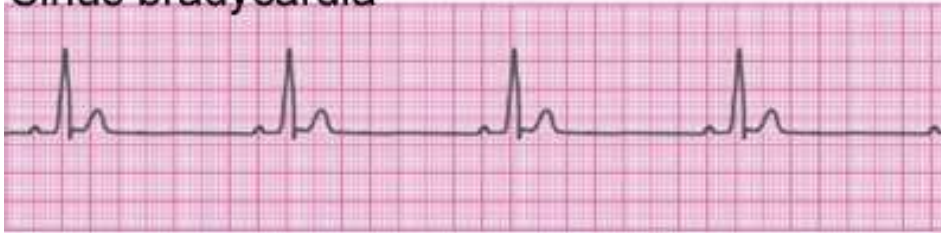

Also known as premature atrial contractions, PACs arise from an atrial stimulus outside of the SA node that fires before the SA node can fire again, resulting in a premature contraction. PACs occur occasionally in most people although they lead to more serious arrhythmias in patients with heart disease and may indicate CHF or imbalance in electrolytes in patients with an MI. This extra stimulus disrupts the pattern of the SA node, causing it to fire early after the PAC.

In some cases, not all of the PACs are conducted through the AV node because they arrive at the node before the AV node is repolarized. PACs are characterized by an irregular rhythm and heart rate that may be increased, a P-R interval that is normal or slightly shortened. P waves from the PAC appear abnormal or may be superimposed on the T wave. The P-R interval is usually normal but may be prolonged. The QRS complex is also usually normal.

PACs that occur every other beat are referred to as atrial bigeminy; and every third beat, as atrial trigeminy and so on.

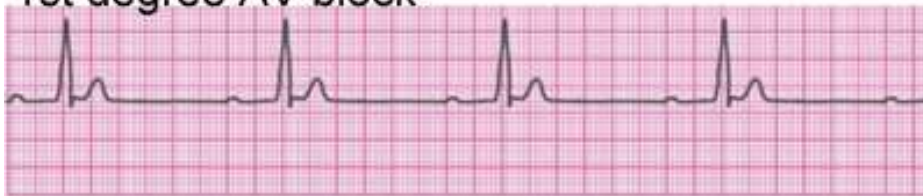### Sinus bradycardia



Sinus bradycardia with a heart rate of less than 60 is a normal variant in some people, such as athletes, and may occur during sleep. Some drugs, such as beta blockers, digitalis, and calcium channel blockers, slow the heart rate and some heart conditions (cardiomyopathy, myocarditis, and post inferior wall MI) as well. Patients are usually asymptomatic until the rate falls below 45 bpm.

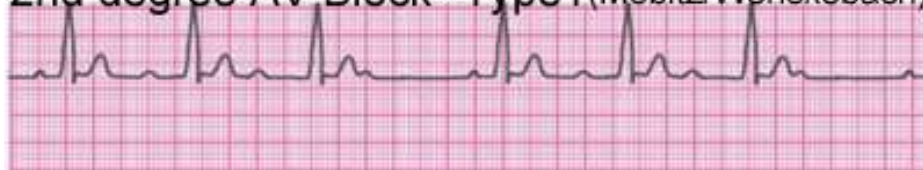Typically, the EKG shows a normal reading except for the heart rate.

### 1st degree AV block



With first degree atrioventricular block, all supraventricular impulses are conducted to the ventricles, but the conduction is prolonged at the AV node. Characteristics include variable heart rate (usually between 60 and 90), regular rhythm, normal P waves that precede each QRS, and prolonged P-R interval (0.20 to 1.0). The QRS complex usually appears normal unless there are other problems, such as a bundle branch block.

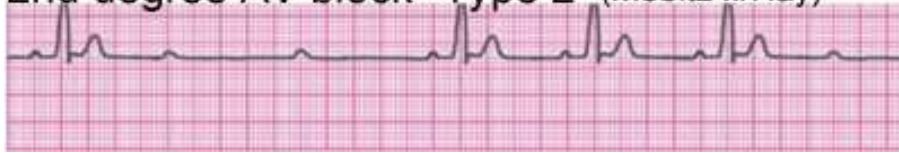### 2nd degree AV Block--Type1 (Mobitz/Wenckebach)



With second degree AV block (also referred to as Wenckebach block or Mobitz type I), the conduction times from atrial impulses become progressively longer until one fails to conduct, resulting in a P wave without a subsequent QRS and a pause, after which the process repeats.

Characteristics include normal heartrate, irregular rhythm (although 2:1 rhythm may occur), gradually prolonged P-R interval, and the QRS complex is usually normal.

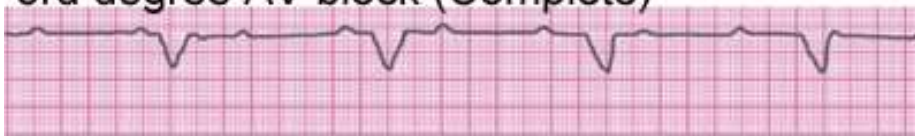### 2nd degree AV block--Type 2 (Mobitz II/Hay)



This AV block is commonly referred to as Mobitz II and occurs when the failure of an impulse to conduct to the ventricles is sudden and not a result of progressive conduction times. This type of block usually results from bilateral bundle branch blocks rather than a block at the AV node.

Characteristics include heartrate variable, irregular rhythm (although blocks may be regular at 2:1), P waves that are usually normal but an occasional P wave may be missing a QRS complex, P-R interval is normal for all conducted beats (before and after blocks), and conduction to the ventricles is slow because of the blocks.

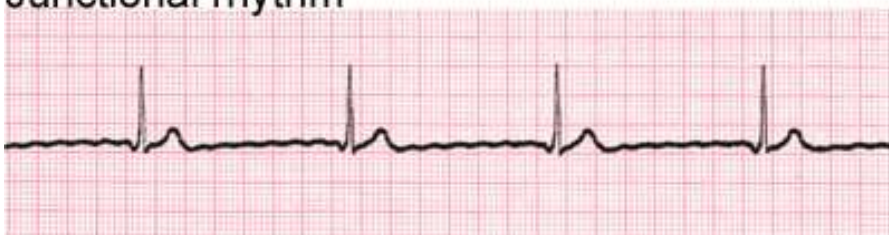### 3rd degree AV block (Complete)



With third degree AV block, all atrial impulses (usually originating in the SA node) are blocked at the AV node or bundle branches.

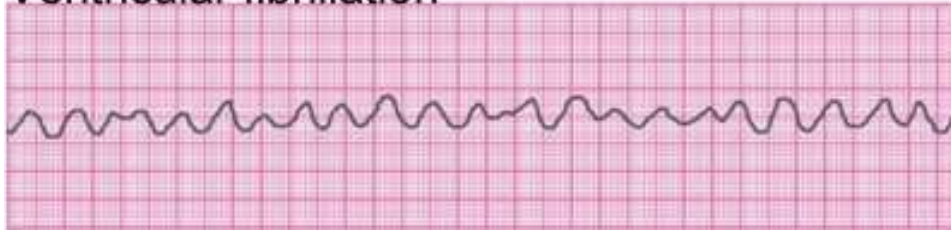Characteristics include a ventricular rate of less than 45 bpm and a regular rhythm. P waves are normal but disassociated from the QRS complex, the P-R interval is inconsistent because the P waves and the QRS are not associated, and the QRS complex is normal if controlled by a junctional pacemaker or wide if controlled by ventricular pacemaker.

### Junctional rhythm



Junctional rhythms occur when electrical stimulation of the ventricles originates near or within the AV node (not the SA node). Characteristics include a regular rhythm but heart rate of less than 60 bpm (although some junctional rhythms are accelerated). The P wave is usually not visible but may be buried in the QRS complex or slightly before or after. The P-R interval is usually abnormally short, less than 0.12 second if a P wave is visible before the QRS complex. If visible, the P wave may be inverted in lead II. The QRS complex, Q-T interval, and ST segment are usually normal.

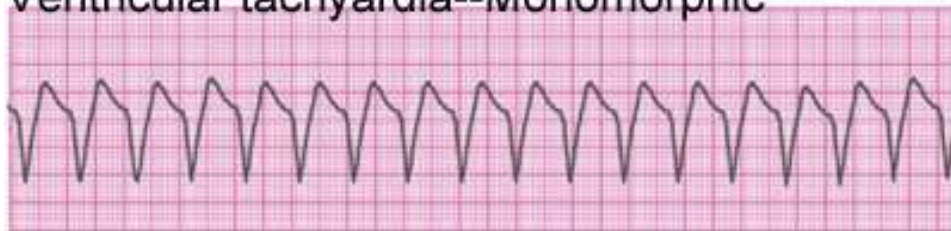### Ventricular fibrillation



VF occurs when the electrical stimulation of the ventricles is chaotic with stimuli arising from various foci but insufficient to adequately contract the ventricles, which instead quiver, so there is no cardiac output. VF may result from MI, myocardial ischemia, electrolyte imbalance, electric shock, hypothermia, and acid-base imbalance.

Characteristics include undetermined rate, rhythm, P wave, P-R interval, duration of QRS complex, or T wave. The EKG shows fibrillatory waves. Note that larger fibrillatory waves (indicating some electrical activity in the heart) are easier to convert than smaller waves.

### Ventricular tachycardia--Monomorphic

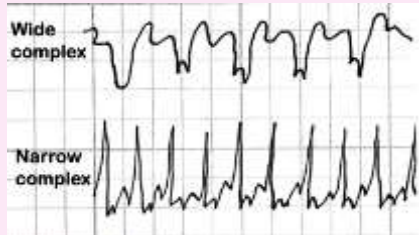


VT (often referred to as V-tach) is an unstable rhythm that occurs with ventricular rates greater than 100 and with 3 or more PVCs in a row. This rhythm often indicates the beginning of cardiac arrest and occurs before ventricular fibrillation.

Characteristics include undetermined atrial rhythm but regular or slightly irregular ventricular rhythm, ventricular rate of 100 to 250 bpm, P waves are usually absent (so unable to determine atrial rate) or not related to QRS complexes, and the P-R wave cannot, therefore, usually be measured. The QRS complex is wide and bizarrely shaped with duration longer than 0.12

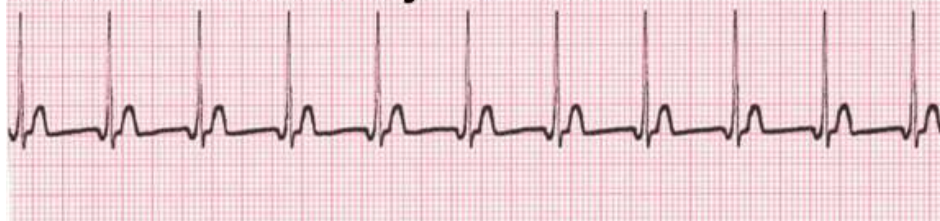second. With monomorphic VT, the QRS look alike; but with polymorphic VT, they appear multiform. Large T waves may follow the QRS but in the opposite direction.

**Note:** Tachycardias are often classified as either wide complex or narrow complex.



Wide complex has a QRS complex greater than 0.12 second; and narrow complex, less than 0.12 second. Wide complex tachycardia originates below the AV node; but narrow complex is supraventricular.

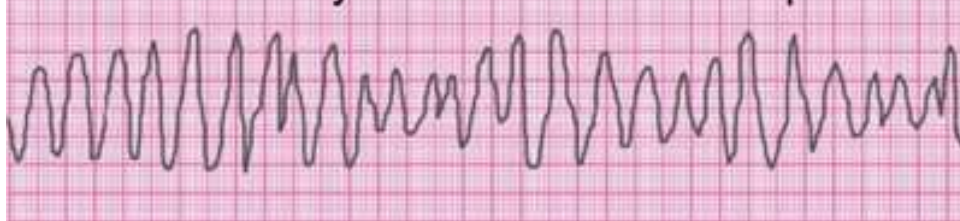## Junctional tachycardia



With this type of supraventricular tachycardia, three or more premature junctional contractions occur one after another when stimuli arise in the AV junctional tissue, overriding the SA node stimuli and taking over as cardiac pacemaker. Thus, the atria are depolarized through retrograde conduction (upward instead of downward).

The heartrate is usually 100 to 200 bpm; and the rhythm, regular. The P wave is typically inverted in leads I, III, and aVF and may precede, follow, or be hidden in the QRS segment. If the P wave precedes the QRS complex, then the P-R interval is less than 0.12 second. The QRS is usually normal, and T wave may appear normal or distorted if the P wave occurs within it. If the heartrate is too rapid, the T wave may be undetectable.

## Ventricular tachycardia--Torsades de pointes



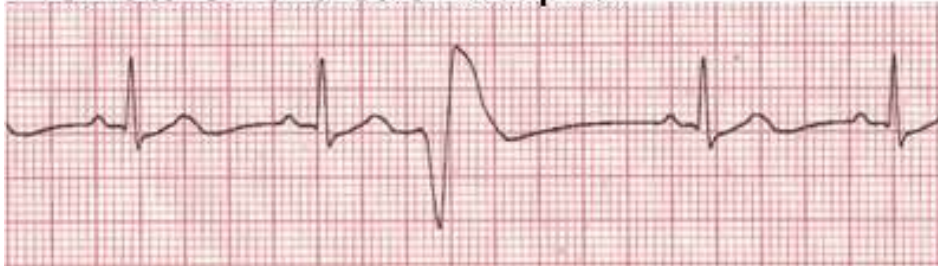Torsades de Pointes (TdP) is a type of polymorphic VT in which the QRS complexes continuously vary and appear to twist, so that the pattern



resembles ventricular fibrillation. This pattern is usually initiated by prolonged QT/QTU intervals that commonly includes a large U wave that follows the T wave or merges with it and wide notched, or biphasic T wave or T wave alternans.

The ventricular rate may vary from 150 to 250 bpm. TdP usually occurs in bursts and is not a sustained rhythm, so it's important to assess the EKG for QT prolongation ( $\geq 0.6$  second/600 ms). TdP may be associated with hypokalemia, hypomagnesemia, and bradycardia.

### Premature ventricular complex

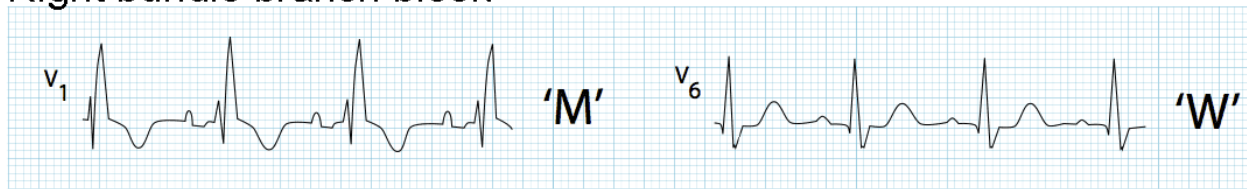


PVCs, also referred to as premature ventricular contractions, are ectopic beats that occur (singly or in clusters) and usually cause no problem in healthy patients; however, if the person has preexisting heart disease, PVCs can indicate high risk for lethal ventricular arrhythmias.

Conduction through the ventricles generally occurs through the muscle cells rather than through the Purkinje fibers. PVCs occur because of premature depolarization of ventricular cells or Purkinje system. PVCs may be associated with hypoxia, myocardial ischemia, electrolyte imbalance (hypokalemia, acidosis), exercise, caffeine, alcohol, and digitalis toxicity.

Heart rate usually is between 60 and 100 and rhythm irregular when ectopic beats occur. The P wave usually does not precede a PVC but one may follow the PVC because of retrograde conduction. There is no P-R interval, but in the rare instance when a P wave precedes a PVC, the P-R interval is shortened. The QRS complex is wide and bizarrely shaped and duration greater than 0.12 second. T waves are generally in the opposite direction from the QRS complex.

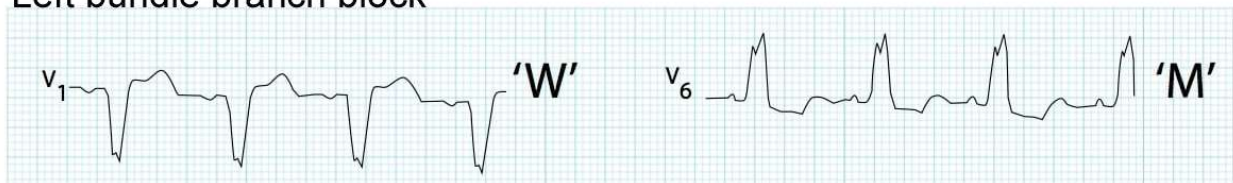
## Right bundle branch block



With RBBB, the depolarisation of the right ventricle is delayed because the block requires that depolarisation spread from the AV node, down the bundle of His and left bundle branch and across the septum from the left ventricle. RBBB is associated with anterior wall MI, pulmonary embolism, and coronary artery disease. RBBB can also occur without preexisting heart disease and, if isolated, is of little concern.

Characteristics include normal P wave, QRS duration greater than 0.12 second if complete block and slightly less if incomplete. The prolonged QRS appears in an M shape in V1 to V3 and a W shape in V6. The S wave is slurred in leads I, aVL, V5, and V6 and deep in V5 and V6. T waves are inverted in the right precordial leads (V1 to V3) and upright in the left. The P-R interval is within normal parameters. The heart rate and rhythm are usually normal.

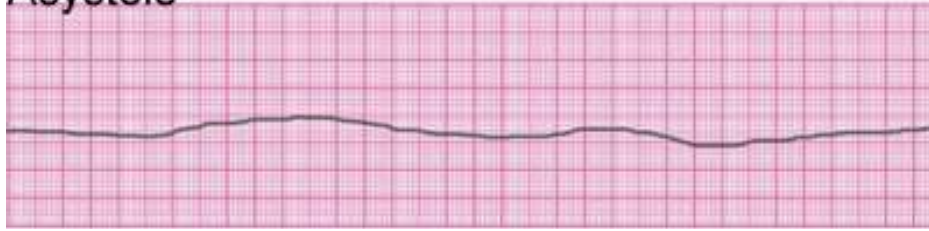
## Left bundle branch block



With LBBB, the depolarisation is essentially in reverse of the RBBB because the conduction spreads first to the right ventricle and then across the septum to the left, resulting in the reverse of the W and M QRS patterns with the W shape in V1 and the M shape in V6. LBBB is associated with aortic stenosis, anterior MI, dilated cardiomyopathy, hyperkalemia, digoxin toxicity, and ischemic cardiac disease.


In a normal heartbeat, the septum is activated from left to right, and this produces small Q waves in the lateral leads, but the LBBB eliminates the septal Q waves in the lateral leads (I, V5 and V6), but small Q waves may be seen in aVL. The QRS duration is extended to greater than 0.12 second. The R wave peak time is prolonged to greater than 0.06 second in the left precordial leads (V6 and V6), and the R waves are tall in the lateral leads (I, V5, V6). S waves are deep in the right precordial leads (V1 and V3)

## Asystole



Asystole occurs when there is no electrical activity in the heart and the patient is in cardiopulmonary arrest. This is a shockable condition.

## Pulseless electrical activity (PEA)



With PEA, the heart muscle is unable to contract even though electrical activity occurs, most often because of hypovolemia and hypoxemia. The EKG may show a normal sinus rhythm, V-tach, bradycardia or other rhythms, but the patient is unconscious, cyanotic and no heartrate is detectable. This is not a shockable condition because the electrical activity of the heart is functioning.

© WWW.RN.C

## References

Coviello, J., ed. *ECG Interpretation Made Incredibly Easy*. Wolters Kluwer, Philadelphia, 2016.

Eccles Health Sciences Library, University of Utah. (n.d.) A method of ECG interpretation. *ECG Learning Center*. Retrieved from <https://ecg.utah.edu/lesson/2>

Jenkins, D & Gerred, S. (2017) ECG Library: Index. *ECG Library*. Retrieved from <https://ecglibrary.com/ecghome.php>

Klabunde, R. E. (2018). Cardiovascular physiology concepts: Index. *CVphysiology*. Retrieved from [https://www.cvphysiology.com/table\\_of\\_contents%20-%20disease](https://www.cvphysiology.com/table_of_contents%20-%20disease)

Lome, S. (2019). 10 steps to learn ECG interpretation. *Healio*. Retrieved from <https://www.healio.com/cardiology/learn-the-heart/blogs/10-steps-course-to-learn-ecg-interpretation>

Reed, A. (2015) *12 Lead EKG for nurses* [booklet]. Nurse mastery.

Woods, S.L et al. (2009). *Cardiac Nursing*, 6<sup>th</sup> ed. New York, Lippincott, Williams and Wilkins.

©www.rn.com